



CERTSWARRIOR

# EMS

## NREMT-Paramedic

### National Registry of Emergency Medical Technicians: National Registered Paramedic

**Questions&AnswersPDF**

**ForMoreInformation:**

**<https://www.certswarrior.com/>**

## Features:

- 90DaysFreeUpdates
- 30DaysMoneyBackGuarantee
- InstantDownloadOncePurchased
- 24/7OnlineChat Support
- ItsLatestVersion

# Latest Version: 6.0

## Question: 1

You hook a patient up to a 12 lead EKG and see a small spike, followed by a normal P wave and QRS complex. Based on your knowledge of irregular waveforms, you recognize this as:

- A. The precursor to ventricular tachycardia
- B. A ventricular pacemaker
- C. Prinzmetal angina
- D. An atrial pacemaker

**Answer: D**

Explanation:

When an atrial pacemaker fires, it will generate a spike followed by a normal P wave and QRS complex. A ventricular pacemaker will produce wide and bizarre QRS complexes.

A PVC is an irregular rhythm that produces wide and bizarre QRS complexes, sometimes consecutively. Ventricular tachycardia is usually preceded by a ventricular rhythm, caused by lethal rhythms such as a third-degree heart block. Prinzmetal angina is characterized by an elevated ST wave.

## Question: 2

You are on-scene with the driver of an automobile in a single-vehicle crash with major front-end damage. You note the smell of alcohol as you introduce yourself to the ambulatory patient. The driver was not wearing a seatbelt, and airbags are not a feature of the automobile he is driving. There is blood in his mouth, though his teeth appear uninjured. He is hoarse when he answers your questions and appears confused.

Which of the following should you suspect is causing the hoarseness in his voice?

- A. Subdural hematoma
- B. Laryngeal injury
- C. Cervical spine injury
- D. Alcohol intoxication

**Answer: B**

Explanation:

The most common cause of laryngeal fracture is a motor vehicle crash. The patient will likely present with difficulty with speech and cough up blood. The paramedic should suspect the presence of a laryngeal injury anytime a trauma patient was struck in the area of the neck and has a hoarse, raspy voice or the inability to talk at all.

It is never appropriate to just assume everything associated with a patient that may have been drinking alcohol is related to intoxication. These patients can still be injured and require care. The effects of a

subdural hematoma are not usually witnessed on-scene and do not include coughing or spitting blood, trauma to the mouth or neck area, or a hoarse, raspy voice. Cervical spine injury is possible even if the patient is ambulatory and is not complaining of neck or back pain. However, it is unlikely the patient's hoarseness and blood in the mouth are caused by a cervical spine injury. The laryngeal injury that caused the potential bleeding is likely to be severe enough to cause a cervical spine injury as well.

### Question: 3

Which of the following is true regarding hip dislocations?  
Select the two answer options which are correct.

- A. Most hip dislocations involve posterior dislocation.
- B. Most hip dislocations involve anterior dislocation.
- C. The leg on the affected side of a posterior hip dislocation will be shortened and internally rotated.
- D. The leg on the affected side of a posterior hip dislocation will be lengthened and externally rotated.

**Answer: A,C**

Explanation:

Over 90% of all hip dislocations involve posterior dislocation. The leg on the affected side of a posterior hip dislocation is typically found in flexion, internally rotated, and noticeably shorter.

The leg on the affected side of an anterior hip dislocation usually presents abducted and externally rotated.

### Question: 4

Your 55-year-old patient is suspected of having a myocardial infarction. He is complaining of substernal chest pain that came on during rest. His heart rate is 88 beats per minute, and his respirations are 20. His skin is cool, pale, and diaphoretic with a blood pressure of 110 systolic.

What does the presence of pale, diaphoretic skin typically indicate during a cardiac event?

- A. Inadequate cardiac output due to myocardial ischemia
- B. Central vasodilation and parasympathetic nervous system stimulation
- C. Peripheral vasoconstriction and sympathetic nervous system stimulation
- D. The heart has lost the ability to be an effective forward pump

**Answer: C**

Explanation:

Patients experiencing a myocardial infarction often suffer from peripheral vasoconstriction, tachycardia, pale cool skin, and diaphoresis as part of the sympathetic nervous system stimulation.

Myocardial infarction patients do not normally experience vasodilation in the central circulation as a result of an MI. Patients experiencing the signs and symptoms associated with inadequate cardiac output or the signs and symptoms that their heart has lost the ability to be an effective forward pump are likely suffering from congestive heart failure and not an infarction. This would likely be evident by the presence of pulmonary edema as a key finding.

### Question: 5

Some cardiac emergency medications are designed to slow conduction through the AV node. To administer these emergency medications safely, the paramedic must ensure which of the following?

- A. The patient is experiencing chest pain
- B. The patient does not have a second-degree AV block type II
- C. The patient has a heart valve prolapse
- D. The patient has a history of heart disease

**Answer: B**

Explanation:

Some emergency medications are designed to slow conduction through the AV node, which is helpful with some forms of tachycardia. To administer the medications safely, the paramedic must make sure that the patient does not have any type of type II atrioventricular block, evidence of disease and dysfunction in both bundle branches, or any two heart blocks.

It is not imperative to know if the patient has a heart disease history, cardiac valve prolapse, or chest pain to administer most emergency medications.

### Question: 6

Which of the following is a potentially life-threatening emergency that most often occurs with injuries above T4 to T6 and results from the loss of parasympathetic stimulation?

- A. Spinal stenosis
- B. Autonomic dysreflexia
- C. Central neurogenic hyperventilation
- D. Spondylolysis

**Answer: B**

Explanation:

Autonomic dysreflexia is a late sign of spinal cord injury. 85% of patients with an injury above T6 will develop this condition. Patients with the condition develop HTN.

Central neurogenic hyperventilation (CNH) is an abnormal pattern of breathing characterized by deep and rapid breaths at a rate of at least 25 breaths per minute. It occurs due to a CNS disorder, and is not a result of parasympathetic stimulation. Spondylolysis is a structural defect of the spine, which is congenital and chronic. Spinal stenosis is a narrowing of the spinal column.

### Question: 7

Which of the following mechanisms of injury should be considered significant, and transported to the highest level TCF available?

Select the two answer options which are correct.

- A. Adult who fell 30 feet
- B. Adult struck by car traveling < 20 mph in parking lot
- C. Adult in auto crash with death in same passenger compartment
- D. Adult in motorcycle crash going 15 mph

**Answer: A,C**

Explanation:

MOIs that should be considered significant, and transported to the highest level trauma center available include:

- Falls
  - o Adults: > 20 feet (one story = 10 feet)
  - o Children: > 10 feet or two to three times the height of the child
- High-risk auto crash
  - o Intrusion, including roof: > 12 inches occupant side; > 18 inches any side
  - o Ejection (partial or complete) from automobile
  - o Death in same passenger compartment
  - o Vehicle telemetry data consistent with a high risk for injury
- Automobile versus pedestrian/bicyclist thrown, run over, or with significant (> 20 mph) impact
- Motorcycle crash > 20 mph

### Question: 8

Which of the following are used to describe specific parts of a motor vehicle?  
Select the two answer options which are correct.

- A. B post
- B. A post
- C. L post
- D. T post

**Answer: A,B**

Explanation:

Using common terminology to describe parts of a motor vehicle helps avoid confusion and can facilitate rescue/extrication. Vehicle anatomy terminology includes the engine compartment, trunk, roof, driver side, passenger side, A post, B post, and C post.

T post and L post are not used in vehicle anatomy terminology.

### Question: 9

Which of the following is considered the most lethal of all the G-series nerve agents?

- A. Soman (GD)

- B. Tabun (GA)
- C. V Agent (VX)
- D. Sarin (GB)

**Answer: A**

Explanation:

G agents came from the early nerve agents and so classified after the German scientists that developed them after WWI and during WWII.

Soman (GD) is twice as persistent as sarin and five times as lethal. It has a fruity odor as a result of the type of alcohol used in the agent and generally has no color.

Tabun (GA) is approximately half as lethal as sarin and 36 times more persistent, and under the proper conditions it will remain present for several days. It has a fruity smell and an appearance similar to sarin.

Sarin (GB) is a more commonly known nerve agent. It is a highly volatile, colorless and odorless liquid. It turns from liquid to gas within seconds to minutes at room temperature. It is highly lethal.

V Agent (VX) is a clear oily agent that has no odor and looks like baby oil. V agent was developed by the British after WWII and has chemical properties similar to the G-series agents. The difference is that VX is more than 100 times more lethal than sarin and is extremely persistent, but is not a G series nerve agent.

### Question: 10

According to research, approximately what percent of patients experiencing a STEMI do not receive pre-hospital ECGs because they do not present with chest pain?

- A. 50%
- B. 10%
- C. 15%
- D. 25%

**Answer: D**

Explanation:

Approximately 25% of patients experiencing a STEMI do not receive pre-hospital ECGs because they do not present with chest pain. This leads to a significant delay in balloon angioplasty. This is why it is important to understand that a pre-hospital 12-lead ECG for any possible symptom of acute coronary syndrome is crucial.

### Question: 11

Your adult patient is unresponsive after a probable narcotic overdose. He has shallow respirations and is diaphoretic. What is your initial treatment?

- A. Administer Narcan 2 mg IN
- B. Administer Romazicon 4 mg IV
- C. Administer Narcan 8 mg IV

D. Administer Narcan 0.4 mg IN

**Answer: A**

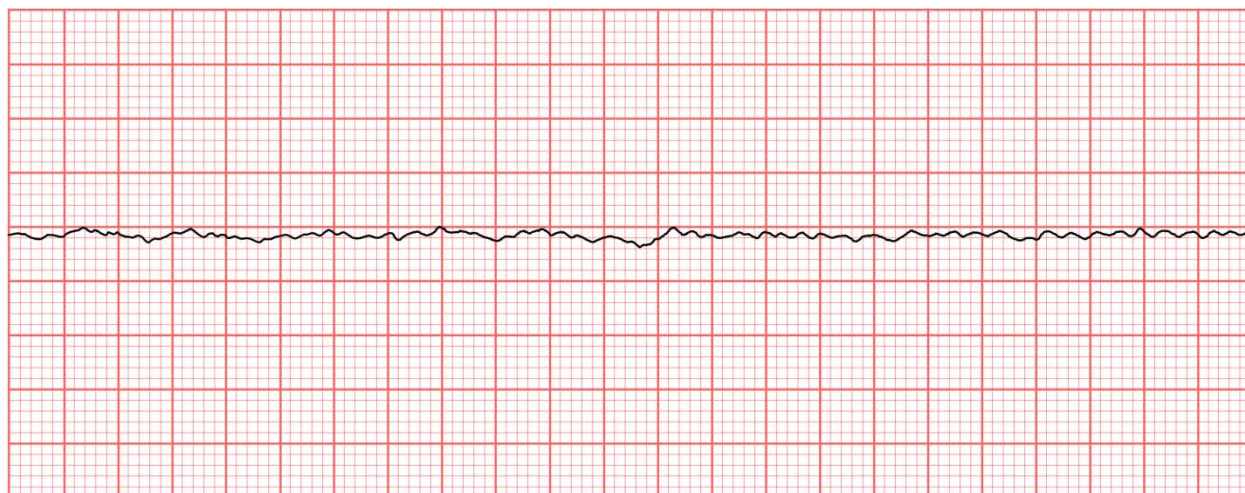Explanation:

The nasal mucosa is very vascular and allows for rapid absorption of some medications such as Narcan. It is considered safer than intramuscular or intravenous routes due to the possibility of unwanted needle sticks when a patient may be combative. The correct dose is 2 mg.

Romazicon is not indicated for a suspected narcotic overdose. Some protocols may allow for the administration of Romazicon for the treatment of benzodiazepine overdose. 8 mg IV of Narcan would not be your initial dose; that is double the amount of the initial dose. 0.4 mg is the initial IV dose of Narcan, not the IN dose.

### Question: 12

What is the next best course of action after seeing this rhythm?



- A. Immediate CPR including defibrillation
- B. Check leads for malfunction
- C. No immediate action at this time
- D. Immediate CPR including cardioversion

**Answer: A**

Explanation:

This rhythm is ventricular fibrillation, a lethal rhythm. There is no cardiac output and, therefore, requires immediate CPR to be performed on the patient. Defibrillation is the immediate course of treatment.

### Question: 13



In which of the following situations would nitroglycerin administration be contraindicated?  
Select the three answer options which are correct.

- A. 12 lead ECG indicates RV infarction
- B. Pulse of 136
- C. 12 lead ECG indicates anterior infarction
- D. SBP is 88 mm Hg

**Answer: A,B,D**

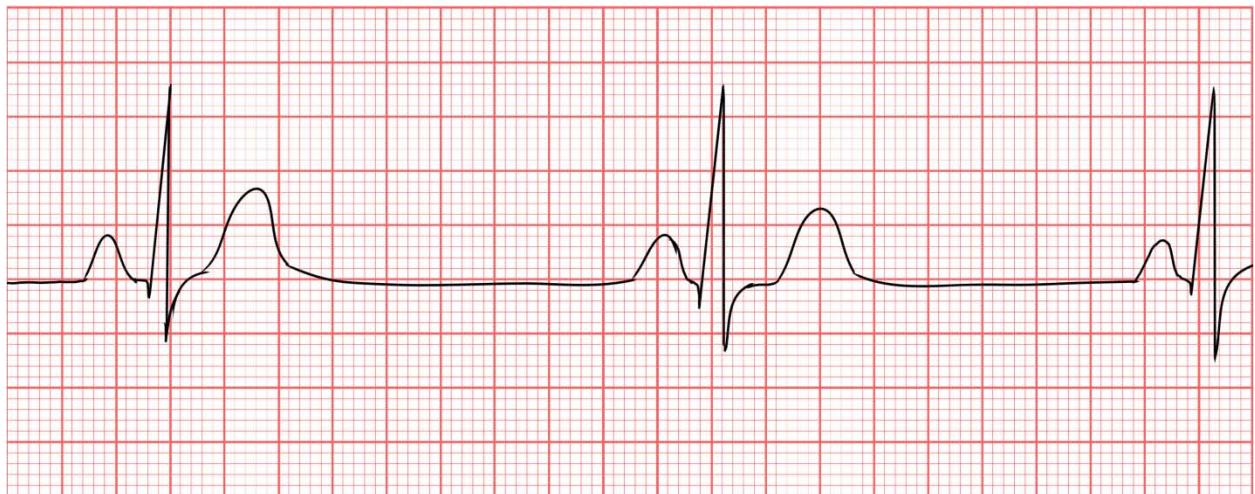Explanation:

Nitroglycerin is a venodilator; use it cautiously or not at all in patients with inadequate ventricular preload such as an inferior wall MI (Myocardial Infarction) and RV (Right Ventricular) infarction. If you confirm RV infarction by right-sided precordial leads, or if an experienced provider confirms it through clinical findings, then nitroglycerin and other vasodilators (morphine) or volume-depleting drugs (diuretics) are contraindicated. Avoid using nitroglycerin in patients with hypotension (SBP less than 90 mm Hg), marked bradycardia (heart rate less than 50/min), or marked tachycardia. Avoid using nitroglycerin if you suspect or know that the patient has taken sildenafil or vardenafil within the previous 24 hours or tadalafil within 48 hours.

An anterior MI is not a contraindication for administration of nitroglycerin; the patient may benefit from it in this case.

### Question: 14

Identify the following rhythm.



- A. Normal sinus rhythm
- B. Type 1 AV block
- C. Sinus bradycardia
- D. Atrial flutter



**Answer: C**

Explanation:

The rhythm pictured is sinus bradycardia, or a sinus rhythm that is less than 60 bpm. It is slower than normal sinus rhythm, which has a rate of 60-100.

A type 1 AV block is an arrhythmia that affects the PR interval. Atrial flutter is an arrhythmia that will show a fluttery pattern instead of P waves. Bradycardia is considered a sinus rhythm that is slower than normal.

### Question: 15

You are on-scene with a 55-year-old cardiac history patient who suddenly collapsed during dinner with his family. He is found to be pulseless and apneic with his family performing adequate CPR on arrival. His wife is distraught and hands you a legal DNR order signed by his physician. She states that he does not have a terminal illness and begs you to ignore the legal order and "do everything in your capabilities to save him!"

Which of the following would be most appropriate in this situation?

- A. Take over CPR until you reach the ambulance, then stop all resuscitation efforts as per the legal order
- B. Abide by the DNR and contact medical control immediately
- C. Provide palliative care only and transport
- D. Advise the family to stop CPR and leave the room

**Answer: B**

Explanation:

In some situations, the family members may disagree with the DNR order and insist that you begin resuscitation. In these situations, avoid any hostile encounters while carrying out the patient's wishes to the best of your ability. Contact medical control in confusing situations involving resuscitation questions. The medical control physician can be a valuable resource in this situation.

The 2020 American Heart Association (AHA) guidelines recommend all EMS providers do not initiate resuscitation of any patient in the following scenarios:

- Situations where attempts to perform CPR would place the rescuer at risk of serious injury or mortal peril
- Overt clinical signs of irreversible death (e.g., rigor mortis, dependent lividity, decapitation, transection, decomposition)
- A valid advanced directive, a Physician Order for Life-Sustaining Treatment (POLST) form indicating that resuscitation is not desired, or a valid Do Not Attempt Resuscitation (DNAR) order

Palliative care is only indicated in DNR patients that are not in cardiac arrest. The DNR order does not give EMS permission to simply "walk away" and do nothing for the patient.

It is important not to be deceptive with the patient's family. You must be honest and provide the facts. Do not ask them to leave the room during this time. The medical control physician may want to speak to the spouse.

Do not take over CPR and then cease resuscitation efforts once in the ambulance. This is dishonest and unethical.

Nationally, most EMS agencies have protocols in place that are in line with the American Heart Association (AHA), the National Association of EMS Physicians (NAEMSP), the American College of Surgeons (ACS), and the American College of Emergency Physicians (ACEP) guidelines.

### Question: 16

Which of the following correctly correlates hemorrhage class with % of blood loss?  
Select the two answer options which are correct.

- A. Class IV 20–40% blood loss
- B. Class II 30–40% blood loss
- C. Class III = 30–40% blood loss
- D. Class I = Less than 15% blood loss

**Answer: C,D**

Explanation:

Classifying hemorrhage will help the paramedic decide on how aggressive to manage fluid resuscitation, and anticipate the severity of shock.

Class I = < 15% blood loss

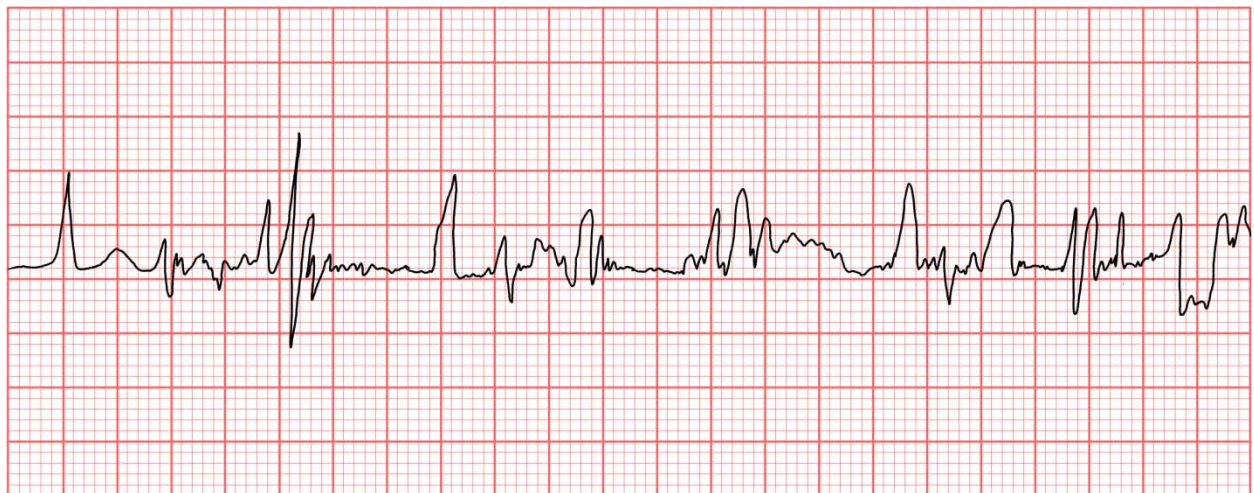Class II = 15-30% blood loss

Class III = 30-40% blood loss

Class IV = > 40% blood loss

### Question: 17

Identify the following artifact.



- A. Somatic tremor
- B. Broken recording
- C. Baseline sway

D. 60 cycle interference

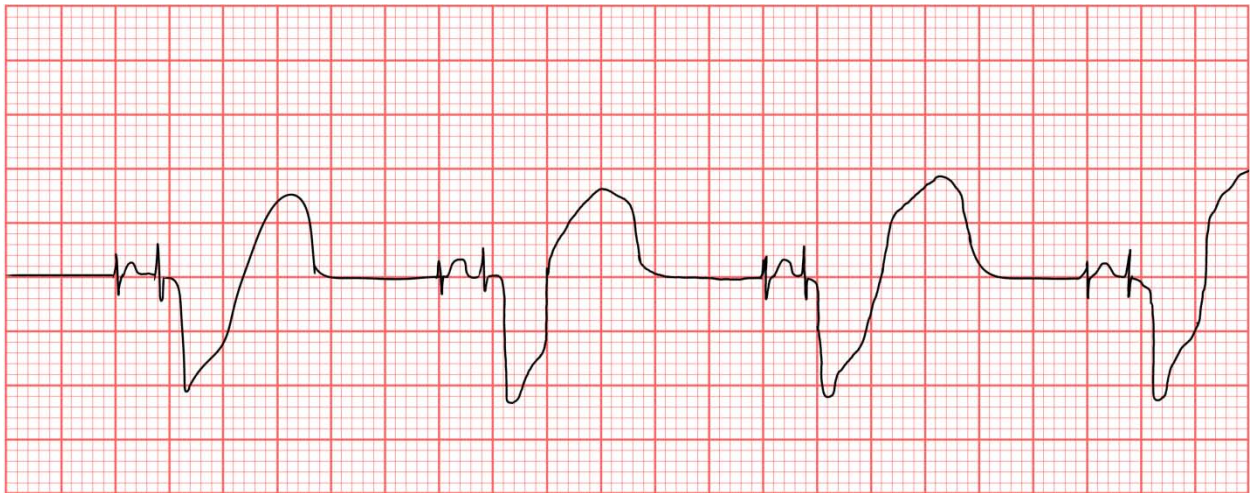
**Answer: A**

Explanation:

A somatic tremor is an artifact usually caused by movement. It can be mistaken for atrial flutter if not examined closely. The artifact can be identified by the shakiness of the rhythm.

### Question: 18

Identify the rhythm.



- A. Cardioversion
- B. Atrial pacing
- C. Ventricular pacing
- D. Dual chamber pacing

**Answer: D**

Explanation:

Dual chamber pacing occurs when the heart is being depolarized by both an atrial and a ventricular pacemaker. This will be evidenced by both a spike preceding the P wave and a spike preceding the QRS complex.

In ventricular pacing, only one spike will appear, preceding each QRS complex. Cardioversion is used when a patient is in acute atrial flutter/atrial fibrillation.

### Question: 19

You are monitoring the cardiac rhythm of your 60-year-old female patient with shortness of breath when you note the presence of a possible first-degree atrioventricular block in lead II on the EKG. Which

of the following electrocardiogram abnormalities makes you think there is a first-degree AV block present?

- A. A P-R interval greater than five small boxes (0.20 seconds) wide on the electrocardiogram tracing
- B. There are more than one P wave for each QRS complex
- C. The P-R intervals become progressively longer until a QRS complex is dropped altogether
- D. The P waves are present but bear no relationship to the QRS complexes

**Answer: A**

Explanation:

A first-degree AV block is not actually a block; it is a delay in the conduction at the level of the AV node. It is characterized by the presence of a lengthened P-R interval. A normal P-R interval is less than five small boxes or 0.20 seconds. It is not usually a treatable condition in the pre-hospital setting and poses no significant threat to the perfusion status of the patient. However, its existence should be noted by the paramedic.

When there are P waves on the electrocardiogram tracing but they show no relationship to the QRS complex, it is indicative of a complete heart block known as a third-degree AV block. It normally indicates there is no communication between the atria and the ventricles. If there is more than one P wave for each regular QRS complex with a widened P-R interval, it is indicative of a second-degree AV block, type II. When the P waves become progressively longer until a QRS complex is dropped altogether, it is indicative of a second-degree AV block type I or Wenckebach.

## Question: 20

While performing a cranial nerve assessment on a patient, what is the reason for having him look straight ahead and follow your outstretched finger with his eyes only?

- A. To assess eye movements controlled by cranial nerve IV
- B. To assess visual acuity controlled by cranial nerve III
- C. To assess eye movement controlled by cranial nerve V
- D. To assess visual acuity controlled by cranial nerve II

**Answer: A**

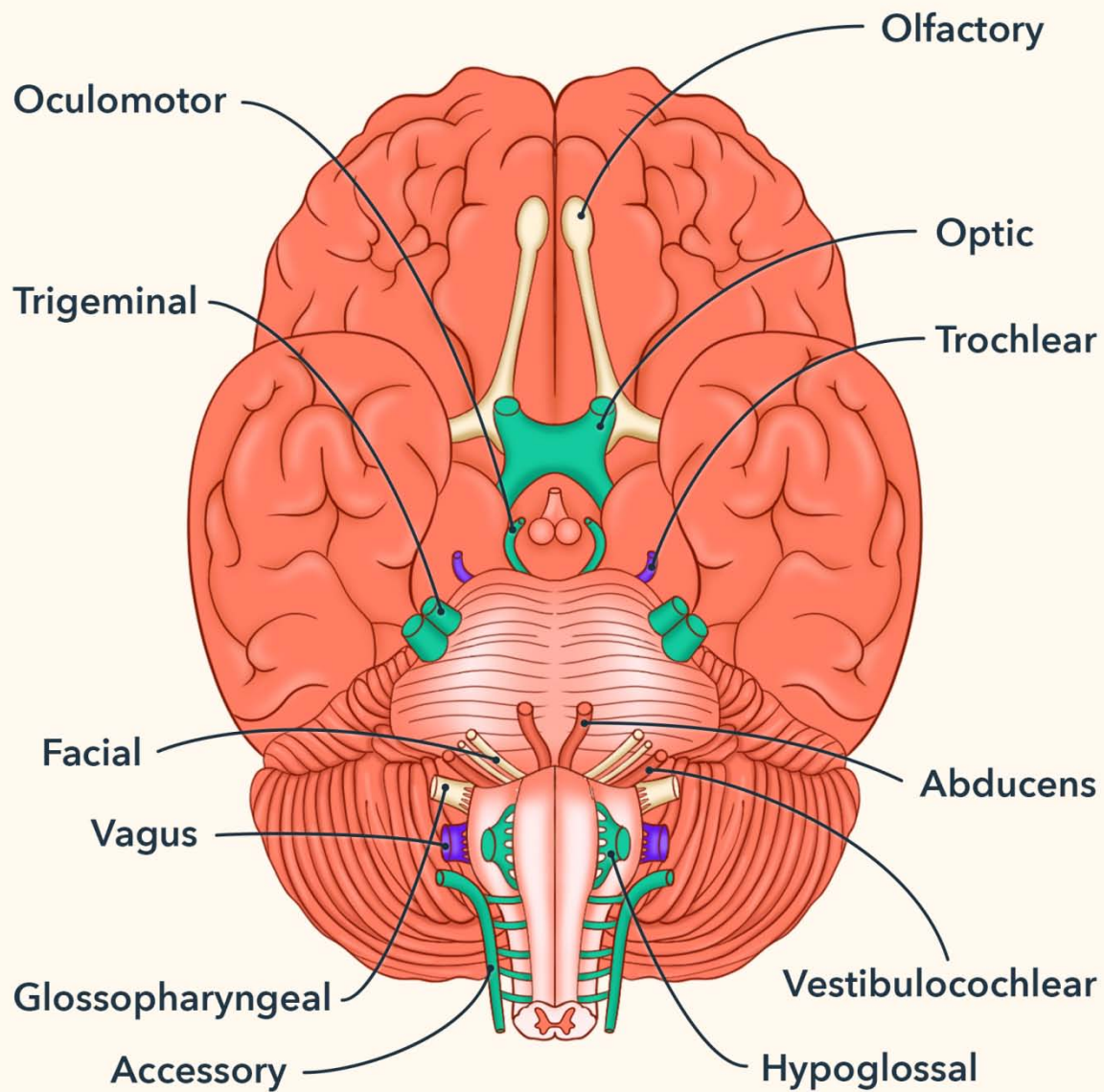
Explanation:

Cranial nerve IV, known as the trochlear nerve, is responsible for eye movements and is best assessed by having the patient look straight ahead and follow your outstretched finger with his eyes only. This simply tests eye movement controlled by the nerve.

Cranial nerve V is the trigeminal nerve responsible for facial sensation, not eye movement. It is best assessed by light touch on the patient's face. Cranial nerve III is the oculomotor nerve, and it is responsible for pupillary reactions to light rather than eye movement. Cranial nerve II is responsible for visual acuity, not eye movement. The best way to test visual acuity is to have the patient identify the outreached finger without moving it.



## Cranial Nerves





# CERTSWARRIOR

## FULL PRODUCT INCLUDES:

Money Back Guarantee



Instant Download after Purchase



90 Days Free Updates



PDF Format Digital Download



24/7 Live Chat Support



Latest Syllabus Updates



For More Information – Visit link below:

**<https://www.certswarrior.com>**

**16 USD Discount Coupon Code: U89DY2AQ**